

A Common Clinical Dilemma: Management of Abnormal Vaginal Cytology and Human Papillomavirus Test Results

Michelle J. Khan, MD, MPH,¹ L. Stewart Massad, MD,² Walter Kinney, MD,³ Michael A. Gold, MD,⁴ EJ Mayeaux, Jr., MD,⁵ Teresa M. Darragh, MD,⁶ Philip E. Castle, PhD, MPH,⁷ David Chelmos, MD,⁸ Herschel W. Lawson, MD,⁹ and Warner K. Huh, MD¹⁰

Objective: Vaginal cancer is an uncommon cancer of the lower genital tract, and standardized screening is not recommended. Risk factors for vaginal cancer include a history of other lower genital tract neoplasia or cancer, smoking, immunosuppression, and exposure to diethylstilbestrol in utero. Although cervical cancer screening after total hysterectomy for benign disease is not recommended, many women inappropriately undergo vaginal cytology and/or human papillomavirus (HPV) tests, and clinicians are faced with managing their abnormal results. Our objectives were to review the literature on vaginal cytology and high-risk HPV (hrHPV) testing and to develop guidance for the management of abnormal vaginal screening tests.

Materials and Methods: An electronic search of the PubMed database through 2015 was performed. Articles describing vaginal cytology or vaginal hrHPV testing were reviewed, and diagnostic accuracy of these tests when available was noted.

Results: The available literature was too limited to develop evidence-based recommendations for managing abnormal vaginal cytology and hrHPV screening tests. However, the data did show that (1) the risk of vaginal cancer in women after hysterectomy is extremely low, justifying the recommendation against routine screening, and (2) in women for whom surveillance is recommended, e.g., women posttreatment for cervical precancer or cancer, hrHPV testing may be useful in identification of vaginal cancer precursors.

Conclusions: Vaginal cancer is rare, and asymptomatic low-risk women should not be screened. An algorithm based on expert opinion is proposed for managing women with abnormal vaginal test results.

Key Words: vaginal cytology, HPV, vaginal cancer, VaIN

(*J Lower Gen Tract Dis* 2016;20: 119–125)

¹Department of Obstetrics and Gynecology, Division of Women's Reproductive Healthcare, University of Alabama at Birmingham School of Medicine, Birmingham, AL; ²Department of Obstetrics and Gynecology, Division of Gynecologic Oncology, Washington University School of Medicine, St. Louis, MO; ³Department of Women's Health, the Permanente Medical Group, Sacramento, CA; ⁴Tulsa Cancer Institute and University of Oklahoma School of Community Medicine, Tulsa, OK; ⁵Departments of Family and Preventive Medicine and Obstetrics and Gynecology, University of South Carolina School of Medicine, Columbia, SC; ⁶Department of Clinical Pathology, University of California, San Francisco, CA; ⁷Department of Epidemiology and Population Health, Albert Einstein College of Medicine, Bronx, NY; ⁸Department of Obstetrics and Gynecology, Virginia Commonwealth University, Richmond, VA; ⁹Department of Gynecology and Obstetrics, Emory University School of Medicine, Atlanta, GA; and ¹⁰Department of Obstetrics and Gynecology, Division of Gynecologic Oncology, University of Alabama at Birmingham School of Medicine, Birmingham, AL

Reprint requests to: Michelle J. Khan, MD, MPH; University of Alabama at Birmingham, 1700 6th Avenue, South WIC 10261, Birmingham, AL 35249. E-mail: mjkh@uabmc.edu

The authors have declared they have no conflicts of interest. Supplemental digital content is available for this article. Direct URL citations appear in the printed text and are provided in the HTML and PDF versions of this article on the journal's Web site (www.jlgt.com).

This Review is published simultaneously in *Gynecologic Oncology* and the *Journal of Lower Genital Tract Disease*.

© 2016, American Society for Colposcopy and Cervical Pathology

Vaginal cancer is a rare human papillomavirus (HPV)-associated gynecologic disease, accounting for approximately 1% to 4% of cancers of the female genital tract.¹ A recent report from the National Program of Cancer Registries and the Surveillance, Epidemiology, and End Results Program estimated that 729 cases of vaginal cancer occurred each year from 2004 to 2008, with approximately 500 attributable to HPV.² The reported incidence rate of vaginal cancer is 0.4 to 0.6 per 100,000 women; by comparison, the incidence rate for cervical cancer in the United States is 7.7 per 100,000 women.^{2,3} Most vaginal cancers are of squamous cell histology; adenocarcinomas and melanomas are seen in smaller numbers.

High-grade squamous intraepithelial lesion (HSIL) or vaginal intraepithelial neoplasia (VaIN) grades 2/3 is a precancerous lesion analogous to HSIL/cervical intraepithelial neoplasia (CIN) grades 2/3.^{4–6} Low-grade squamous intraepithelial lesion (LSIL) or VaIN 1 is a benign manifestation of HPV infection. Although natural history data on VaIN are scarce, it is thought that invasive vaginal cancer, such as invasive cervical cancer, is caused by persistent high-risk HPV (hrHPV) infection.⁷ Other known risk factors for vaginal cancer include age at first intercourse younger than 17 years, 5 or more lifetime number of sexual partners, immunosuppression, smoking, pelvic radiation therapy, and exposure to diethylstilbestrol in utero.^{4,8} Women who have had cervical cancer are also at significantly increased risk of developing vaginal cancer.⁷ Age is also a risk factor for precancerous lesions of the vagina: HSIL/VaIN 2/3 was found more often in women older than 50 years compared with LSIL/VaIN 1 (mean age = 45 years).⁹ The Centers for Disease Control and Prevention reported that the mean age at diagnosis of vaginal cancer was 69 years, 2 decades later than the mean age of cervical cancer of 48 years.¹⁰

There are no recent population-based studies that provide an accurate estimation of the incidence of VaIN, but extrapolating from older data, the incidence is thought to be approximately 0.2 to 0.3 per 100,000 women in the United States.¹¹ Vaginal intraepithelial neoplasia incidence may be rising as a result of increased sexual exposure to hrHPV with changing sexual behavior for the past several decades, as well as with improved detection with widespread sensitive cervical cancer screening tests and colposcopy.¹² The estimated progression rate of VaIN to vaginal cancer ranges from 0% to 9% in 5 different studies. These studies included cases of women with VaIN grades 1–3 who progressed to invasive vaginal cancer. These reported rates of progression are much lower than the demonstrated up to 30% progression rate for CIN 3 to invasive cervical cancer.^{1,7–9,13–16}

Because of the rarity of vaginal cancer, there are currently no formal guidelines recommending screening for vaginal cancer in the general population (see Table 1). In fact, research articles and professional society guidelines recommend against vaginal cancer screening in women posthysterectomy for benign disease and in women posthysterectomy for cancers other than cervical cancer.^{19–22} However, current cervical cancer screening guidelines do recommend that high-risk groups such as women who have

TABLE 1. Current Screening Guidelines for Vaginal Cancer

Population	Recommended screening method
Healthy asymptomatic women with a cervix undergoing annual gynecologic examination, no prior history of cervical dysplasia	None; cervical cancer screening per ASCCP/ASCP/ACS and USPSTF guidelines ^{19,20}
Healthy asymptomatic women posthysterectomy for benign disease undergoing annual gynecologic exam; no previous history of cervical dysplasia	None
Women with history of cervical precancer (CIN 2, CIN 2/3, or CIN 3) with a cervix	Cervical cancer screening per ASCCP 2012 management guidelines ³⁹
Women with history of cervical precancer or cervical cancer posthysterectomy	Per ASCCP 2012 and NCCN management guidelines ^{39,40}

ASCCP indicates the American Society for Colposcopy and Cervical Pathology. ASCP indicates the American Society for Clinical Pathology. ACS indicates the American Cancer Society. USPSTF indicates the United States Preventive Services Task Force. CIN indicates cervical intraepithelial neoplasia.

had cervical precancer (HSIL/CIN 2/3) or invasive cervical cancer undergo continued surveillance testing for at least 20 years after treatment.¹⁹ By this definition, women with a history of cervical precancer who subsequently undergo hysterectomy will still require vaginal cytology screening for at least 20 years after their treatment for cervical precancer.

Despite guidelines recommending against vaginal cancer screening for women posthysterectomy for benign conditions and no history of precancer (see Table 1), many such women have cytology and/or cotesting (cytology + hrHPV testing) performed.^{19,23} This leaves clinicians with the dilemma of how to manage these abnormal vaginal screening tests. The objective of this article is to review the literature on vaginal cytology and hrHPV testing and their accuracy in prediction of VaIN/cancer and to provide guidance on how to best manage women who were screened inappropriately after hysterectomy, as well as women undergoing surveillance after treatment for cervical HSIL/cancer. For women screened inappropriately, we aim to provide guidance for discontinuation of further testing.

Unlike the consensus management guidelines for abnormal cervical cancer screening results and diagnosed cervical precancer published by the ASCCP, this guidance is based expressly on expert opinion, because there are no large clinical trials or rigorous epidemiologic studies of vaginal cancer screening on which to base our recommendations.

MATERIALS AND METHODS

We performed a search of the PubMed database through June 2015 using the keywords “vaginal intraepithelial neoplasia,” “vaginal dysplasia,” “HPV DNA testing,” “hysterectomy,” “vaginal cancer,” and “HPV/human papillomavirus.” We also searched the references of retrieved articles. Articles were reviewed if they reported on vaginal screening tests and reviewed at least 20 histologically confirmed cases of vaginal cancer and/or VaIN. Studies were excluded if they did not distinguish between CIN and VaIN, to be able to extract data for VaIN alone. Abstracts, letters to the editor, and studies written in any language other than English were excluded. For each study meeting the inclusion criteria, data were extracted about author, year of publication, country of publication, sample size, presence of hysterectomy, cytologic

and histopathologic information, HPV test used, and results including genotyping, if available.

RESULTS

A total of 2,478 titles were retrieved using the search terms described. The majority were excluded by their title and the remainder after reviewing the abstract or complete article. A total of 325 abstracts were reviewed and 18 studies met inclusion criteria after full text review (Table, Supplemental Digital Content, <http://links.lww.com/LGT/A29>).

Human Papillomavirus Attribution and Genotype Distribution Among VaIN and Vaginal Cancers

Smith et al.⁵ performed a systematic review of the literature and looked at the HPV attribution among 66 LSIL/VaIN 1, 166 HSIL/VaIN 2/3, and 83 invasive vaginal cancer cases. Overall, HPV prevalence was 98.5% in LSIL/VaIN 1, 92.6% in HSIL/VaIN 2/3, and 65.5% in invasive vaginal cancer. All of the HPV-positive vaginal cancers and the vast majority of the HPV-positive HSIL/VaIN 2/3 lesions tested positive for hrHPV types. Another concurrent meta-analysis found HPV attribution of 100% in LSIL/VaIN 1, 90.1% in HSIL/VaIN 2/3, and 69.9% in invasive vaginal cancer.²⁴ A Swedish study of 69 vaginal cancer cases found HPV positivity in 37 cases (53.6%), with 70.3% testing positive for HPV 16 and 5.4% for HPV 18, 31, 33, and 52.¹⁷ In a recent study of invasive vaginal cancers from population-based registries in the United States, hrHPV testing was performed on 60 cases and 75% tested positive for hrHPV.²⁵ Finally, in a worldwide study of 189 HSIL/VaIN 2/3 and 408 invasive vaginal cancer cases that were individually tested for HPV, overall HPV positivity was found in 74% of the invasive vaginal cancers and 96% of the HSIL/VaIN 2/3.²⁶ In all of these studies, HPV 16 was the most common hrHPV type detected in VaIN and vaginal cancers.^{5,23,25–27} The next most common hrHPV types were HPV 18, 31, 33, and 52, although their prevalence was much lower than HPV 16.

In summary, hrHPV positivity was found in 99% to 100% of LSIL/VaIN 1, in 90% to 96% of HSIL/VaIN 2/3, and in 54% to 75% of invasive vaginal cancers.

Vaginal Cytology for Detection of VaIN and Vaginal Cancer

Few studies have examined the use of vaginal cytology for detection of VaIN. The largest cohort that examined vaginal

cytology results after hysterectomy was by Pearce et al.²⁹ in 1996. A total of 9,610 vaginal cytology samples were obtained from 5,682 women posthysterectomy for benign gynecologic disease for a 3-year period, for an average of 1.7 smears per woman. Of the 9,610 cytology samples, 104 (1.1%) were abnormal, including 0.5% atypical squamous cells of undetermined significance (ASC-US), 0.5% LSIL, 0.1% HSIL, and 0.02% squamous cell carcinoma (SCC). There were no biopsy-proven vaginal cancer cases and there were only 6 cases of LSIL/VaIN 1 or HSIL/VaIN 2. The positive predictive value (PPV) of vaginal cytology was 0% for HSIL/VaIN 3 and vaginal cancer and 6.3% for VaIN 1/2.

Frega et al.³⁰ studied 830 women who had a hysterectomy and on whom they performed vaginal cytology, colposcopy with biopsy of lesions, and hrHPV testing via polymerase chain reaction for a follow-up of 2 to 5 years (mean = 3 years). Thirty women had HSIL/VaIN 2/3, of whom 25 (83.3%) tested “positive” by cytology, the definition of positive cytology was not defined by the authors. Of the 2 women who developed cancer after VaIN 3, both had been positive by cytology at their initial VaIN 3 detection.

A study by So et al.⁹ reported on 48 women with VaIN, of which 37 had follow-up information. The women were followed every 3 to 6 months by colposcopy, cytology, and hrHPV testing for a mean of 30 months (range = 12–72 months). On follow-up after treatment, 70.3% of patients had resolution of the VaIN lesion(s) and none progressed to invasive vaginal cancer. The authors reported no significant association of cytologic result with grade of VaIN at the initial visit. They combined “within normal limits” and ASC-US into 1 category and LSIL and HSIL into another and reported that the diagnostic accuracy of cytology for diagnosis of persistent VaIN at a threshold of LSIL or higher was the following: sensitivity, 18.2%; specificity, 96.2%; PPV, 66.7%; and negative predictive value (NPV), 73.5%.

Bansal et al.³¹ retrieved test information on 2,892 women with posthysterectomy vaginal cytology and HPV testing data in the pathology archives for a 4-year period. Interestingly, 1,320 (45.6%) of the cytologic specimens were reported to contain a squamous cell abnormality, including 1,125 ASC-US (85%), 148 LSIL (5.1%), 36 atypical squamous cells cannot rule out high grade (ASC-H, 3%), and 11 (1%) HSIL. Of the 148 women with LSIL, 76.4% (95% CI = 69.5%–83.2%) had a positive hrHPV test. They focused the analysis on 59 women with LSIL vaginal cytology who were followed for 0.2 to 43 months (median = 13 months) and had follow-up histology. They found that 41 (69.5%) were diagnosed with LSIL/VaIN 1 and 7 (14.6%, 0.2% of all the cytology samples) were diagnosed with HSIL/VaIN 2/3. They concluded that the PPV of LSIL vaginal cytology for HSIL/VaIN 2/3 is 14.3%.

In summary, a precise estimate of the accuracy of vaginal cytology for prediction of HSIL/VaIN 2/3 and vaginal cancer is limited by the few available studies. The sensitivity was 83% in 1 prospective study.³⁰ The PPV of cytology for HSIL/VaIN 2/3 and vaginal cancer ranges from 0% to 14%.

Human Papillomavirus Testing for Detection of VaIN and Vaginal Cancer

There is currently no Food and Drug Administration–approved hrHPV test for use in screening for vaginal cancer or precancer; however, women who receive inappropriate screening after hysterectomy for benign disease often have hrHPV or cotesting results that require interpretation and management.

Human papillomavirus infection of the vagina is as common as HPV infection of the cervix. Castle et al.³² studied the prevalence of vaginal HPV in 569 women posthysterectomy within a

natural history cohort in Guanacaste, Costa Rica, and compared age-standardized prevalence of HPV in vaginal specimens to cervical specimens from 6,098 women who did not have a hysterectomy. The prevalence of hrHPV was not significantly different in women who had undergone hysterectomy (9.5%; 95% CI = 5.0%–14.1%) compared with those who had an intact uterus (9.3%; 95% CI = 8.6%–10.0%). Another study by Castle et al.³³ at Kaiser Permanente in Portland, Oregon, compared HPV prevalence among women who had a hysterectomy with those who had not, and they found no significant differences in hrHPV between the 2 groups (4.5% in women who had undergone hysterectomy, 6.5% in those who had not).

Only 1 prospective cohort study has examined hrHPV prevalence and its relation to VaIN and vaginal cancer. Frega et al.³⁰ studied 830 women as noted previously. Most women (728/830) had hysterectomy for a gynecologic malignancy, so this was a high-risk population for vaginal cancer. Forty-four cases of VaIN were reported (5.3% of the study population; 14 VaIN 1, 24 VaIN 2, 6 VaIN 3), and all (100%) tested hrHPV positive with 91% testing positive for HPV 16 and 9% testing positive for HPV 18. Two (33%, 0.2% of the entire study population) of the 6 women with HSIL/VaIN 3 progressed to cancer over a 3-year follow-up period. High-risk human papillomavirus testing had a sensitivity of 90%, specificity of 78%, PPV of 56%, and NPV of 92% for persistence/progression of VaIN.

Most of other studies that evaluated hrHPV testing in VaIN lesions were retrospective pathology studies that performed HPV testing on vaginal biopsy specimens.^{4,18,34–37} Several of these studies were included in the systematic reviews of HPV attribution in VaIN and vaginal cancers and we will not discuss them further.^{5,24,28} Regardless, the findings illustrate the prevalence of hrHPV in the vagina and may shed some light on the utility of hrHPV testing for detection of VaIN.

In the study by So et al.⁹ discussed previously, 48 women with VaIN were tested for hrHPV and were followed for up to 72 months. They found that 74.3%, 85.7%, and 100% of LSIL/VaIN 1, HSIL/VaIN 2, and HSIL/VaIN 3 lesions, respectively, tested positive for hrHPV. This was the only study to report on HPV viral load, and they found higher loads in HSIL/VaIN 2/3 compared with LSIL/VaIN 1 ($p = .009$). Higher HPV viral loads were also found in the women with persistent VaIN compared with the women who had regression of their lesion(s) ($p < .001$). They calculated the diagnostic accuracy of hrHPV testing for prediction of persistent VaIN: sensitivity, 81.8%; specificity, 88.5%; PPV, 75.0%; and NPV, 92.0%.

In the Bansal study noted previously, 34 (82.9%) of the 148 LSIL/VaIN 1 cases and all of 11 HSIL/VaIN 2/3 cases tested positive for hrHPV.³¹ The calculated sensitivity of hrHPV testing for prediction of HSIL/VaIN 2/3 was 100%, specificity 21%, PPV 15%, and negative predictive value 100%.

Chao et al.³⁸ performed HPV testing using polymerase chain reaction on 394 VaIN tissue blocks. They found that 69.3% of VaIN tissue blocks tested positive for HPV, and of those that tested positive, 17.9% had multiple HPV types present. The most common types present in the HPV-positive tissue blocks were HPV 16 (35.5%), HPV 58 (9.9%), HPV 39 (8.4%), HPV 33 (7.3%), and HPV 53 (7.0%).

In summary, hrHPV infection of the vagina is just as common in women posthysterectomy as those with an intact uterus. A precise estimate of the accuracy of vaginal hrHPV testing for prediction of HSIL/VaIN 2/3 is limited by the few available studies. The sensitivity ranges from 82% to 90% for prediction of VaIN persistence/progression to 92% to 100% for prediction of HSIL/VaIN 2/3. The PPV ranges from 15% for prediction of HSIL/VaIN 2/3 to 75% for prediction of VaIN persistence/progression.

DISCUSSION

Management of Abnormal Vaginal Screening Tests

Expert authors recommend applying some lessons learned from cervical cancer prevention guidelines to management of abnormal vaginal screening tests. For example, although hrHPV testing is not Food and Drug Administration approved for use on specimens obtained from the vagina, given the high prevalence of hrHPV in HSIL/VaIN 3 and vaginal cancer, the negative predictive value of a hrHPV test is very high and therefore reassuring that there is low risk of vaginal cancer. Accordingly, healthy asymptomatic women with negative hrHPV testing and a negative cytology are at extremely low risk and do not require future testing if they have had hysterectomy for benign disease and have no history of cervical precancer or cancer. The PPV of hrHPV testing for vaginal cancer and its precursors is less clear, because few studies have reported on hrHPV testing in women without histologically confirmed VaIN, but it is expected to be low as noted in the preceding section.

As noted previously in two of the studies that reported on vaginal cytology after hysterectomy, the PPV of cytology for HSIL/VaIN 2/3 ranges from 0% to 6% in the Pearce study²⁹ to 14%³¹ in the Bansal study. The PPV from the Bansal study likely represents an overestimate, because only 40% of women with LSIL had biopsies done and case histories were unknown, so decision for biopsy might have been biased toward higher-risk women. It is clear from this study that vaginal cytologic abnormalities are common in women posthysterectomy; because hysterectomy indications and prior CIN were unknown, the generalizability of this result to most women who have had hysterectomies is unclear. The PPV for persistent VaIN was 67% in the So study, but it is unclear which grade of VaIN was persistent in the 11 women. Given the low PPV estimates for both vaginal cytology and hrHPV testing, we favor a conservative approach to management of abnormal vaginal tests.

Although we can use some of the knowledge we have gained from studies of the natural history of HPV-related cervical lesions to decide how to manage women with VaIN, it is important to keep in mind that vaginal cancer incidence is an order of magnitude lower than cervical cancer incidence, and as such, we must be careful not to overscreen and overevaluate women for a rare condition. Women with a history of recent treatment for HSIL/CIN 2/3 or cervical cancer must undergo surveillance according to national guidelines. The following guidance applies to women without a history of HSIL/CIN 2/3 or cancer who were inappropriately screened using cytology or cotesting or those with a history of HSIL/CIN 2/3 or cancer who have completed the recommended surveillance after treatment and are now in follow-up for at least 20 years posttreatment.^{39,40} Although women posttreatment for HSIL or cancer are at higher risk for vaginal cancer than women posthysterectomy for benign disease, most disease recurrence occurs within the first 2 to 3 years posttreatment, and their risk goes down substantially after repetitive negative screening tests.⁴¹ We therefore reasoned that the women posttreatment for HSIL or cancer can be managed similarly as the low-risk women after they have had negative posttreatment surveillance tests and are back to "routine surveillance" for at least 20 years.

An ASC-US result on vaginal cytology, similar to cervical ASC-US, is a nonspecific equivocal result and as such should have some type of triage test to lead to the next step in management, i.e., vaginal colposcopy. An LSIL result is indicative of a benign HPV infection and is likely to test hrHPV positive. We propose that vaginal colposcopy should be deferred and vaginal cotesting be repeated in 1 year for women with either ASC-US

or LSIL vaginal cytology, and if persistently abnormal or hrHPV positive (hrHPV+), the woman should undergo vaginal colposcopy with biopsy of any lesions (see Figure 1). Alternatively, because most HPV-positive vaginal cancers are HPV 16/18 positive, genotyping can be conducted, with immediate colposcopy if HPV 16/18 positive with ASC-US or LSIL and observation for up to 2 years in women who are HPV 16/18 positive with negative cytology or women who are HPV 16/18 negative with ASC-US or LSIL.¹⁷ Women who cotest negative/negative can return to routine screening, which should be cessation of screening if they had hysterectomy for benign disease or continued surveillance for 20 years if they have had HSIL or cancer. If HPV testing is not available, cytology can be repeated 1 year after an initial ASC-US or LSIL, and if any abnormality is reported (e.g., ≥ASC-US), the woman should be referred for colposcopy. Given the lower sensitivity and negative predictive value of cytology compared with cotesting, 2 negative cytology results should be documented before returning to routine surveillance or cessation of screening.

High-grade squamous intraepithelial lesion vaginal cytology should prompt timely vaginal colposcopy with biopsy of any suspicious-appearing lesions. As noted in our literature review, HSIL vaginal cytology is rarely encountered. If vaginal colposcopy is negative after HSIL cytology, we would recommend repeat vaginal cytology and colposcopy in 6 to 12 months. No evidence exists to guide management of women with atypical glandular cells (AGC) or ASC-H cytology after hysterectomy. We recommend the same management as after HSIL cytology.

Finally, women with a positive hrHPV test and negative cytology should have repeat cytology or cotesting in 1 year. Any abnormalities at the repeat test should prompt vaginal colposcopy.

This guidance for follow-up of women with abnormal vaginal testing results also applies to women who are appropriately undergoing vaginal surveillance, with the caveat that surveillance should continue for at least 20 years after treatment for HSIL or cancer even after negative/negative cotesting.³⁷ National guidelines do not specifically state the interval for surveillance after the first 5 years posttreatment, but we would propose that women with negative/negative cotesting undergo surveillance tests at 3-year intervals.³⁹ This guidance applies only to asymptomatic women and should not be extended to women with abnormal vaginal cytology who have symptoms, especially bleeding, or visible vaginal lesions.

Vaginal Colposcopy

Most colposcopists have plentiful experience with examining the cervix, but vaginal lesions are less commonly encountered in clinical practice. It is important to remember certain principles when performing a colposcopy of the vagina.⁴² Unlike the cervix, the vagina is not easily visualized in a static colposcopy. There are multiple folds and areas covered by the speculum requiring that the colposcopist manipulate the speculum during the colposcopic examination to view all of the walls of the vagina as well as the fornices. It is important to apply a dilute solution (3%–5%) of acetic acid to the entire vaginal mucosa and to wait at the minimum 1 to 2 minutes for acetowhite changes to appear. The colposcopic findings in vaginal lesions include acetowhite epithelium, punctation, color changes, and ulceration; mosaicism is rarely seen in the vagina. In the absence of iodine allergy, Lugol's iodine should also be applied to confirm the presence or absence of an abnormal area of epithelium; Lugol's nonstaining areas are seen in VaIN lesions. The most common place for VaIN to be present in a woman posthysterectomy is at the vaginal cuff. It is important to take a biopsy when a lesion is identified at vaginal colposcopy, because the

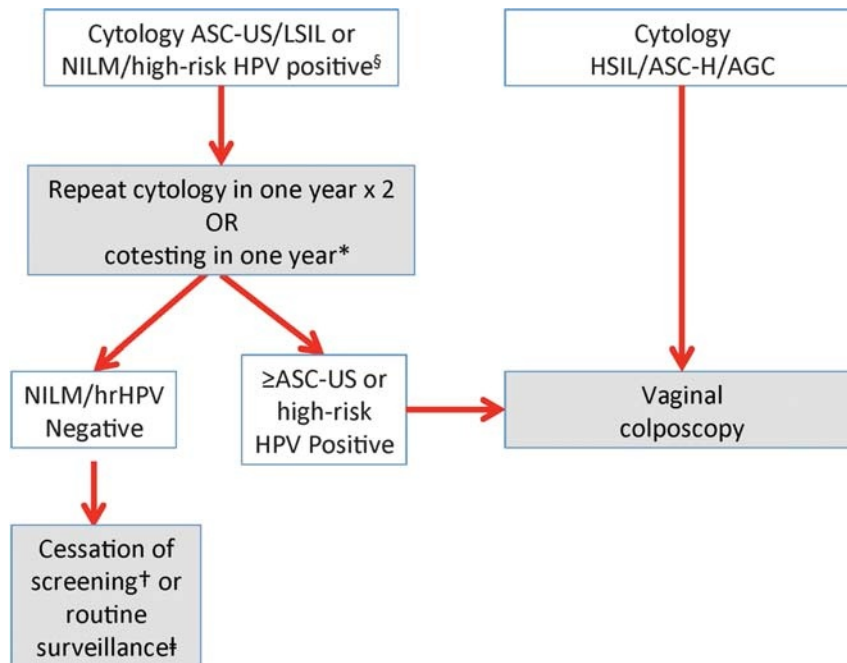


FIGURE 1. Proposed management algorithm for abnormal vaginal cancer screening tests in women with a history of hysterectomy. Footnote: *Cotesting = cervical cytology + hrHPV testing. Given the high negative predictive value of HPV testing, only 1 cotest is needed. Repeat cytology every year should be performed at least twice. If cotest negative \times 1 or cytology negative \times 2, it can stop screening †(posthysterectomy for benign disease) or continue routine surveillance † (posttreatment for cervical HSIL or cervical cancer). §If HPV genotyping is available, recommend immediate colposcopy for ASC-US/LSIL with HPV 16/18 positive and repeat testing in 1 year for those with NILM cytology/HPV 16/18 positive or HPV 16/18 negative. ASC-US indicates atypical squamous cells of undetermined significance; LSIL, low-grade squamous intraepithelial lesion; HSIL, high-grade squamous intraepithelial lesion; ASC-H, atypical squamous cells cannot rule out high-grade; AGC, atypical glandular cells; NILM, negative for intraepithelial lesion or malignancy.

histology will help to distinguish between normal epithelium, a benign, productive VaIN 1 lesion, and a true cancer precursor. Lesions in the upper two thirds of the vagina do not generally require anesthetic prebiopsy; however, there are more nerve endings in the lower one third of the vagina and topical or injectable anesthetic may be needed before biopsy. Vaginal colposcopy should be performed by clinicians with higher volume experience in vaginal colposcopy.

Treatment for VaIN

Vaginal intraepithelial neoplasia can be treated by several different modalities and there is currently no standard of care as to which method is superior. The choice of treatment method should therefore take into account the patient's preference as well as the experience and training of the treating provider (see Table 2). In general, it is not recommended to treat LSIL/VaIN 1 lesions because these lesions usually represent a benign productive HPV infection; however, there may be clinical situations in which treatment is preferred such as cosmetic treatment for bulky or bleeding warts.

Treatment is recommended for histologic HSIL/VaIN 3, which is considered the precursor lesion to vaginal cancer. Vaginal intraepithelial neoplasia 2 represents an equivocal diagnosis that has the potential to regress; if p16 immunostaining is performed and negative, it would be reasonable to conservatively follow patients with VaIN 2.⁶ However, VaIN 2 with positive p16 staining should be considered a true precancer and should be treated.

Several studies have reported on the various methods of treatment, which include topical medications (imiquimod, 5-fluorouracil, trichloroacetic acid, intravaginal estrogen),

CO₂ laser ablation, excision/vaginectomy, cavitation ultrasonic surgical aspiration, and radiation therapy.^{43,44} In our experience, the most common therapies include CO₂ laser ablation and excision/vaginectomy. Topical options can be considered for patients who are not good surgical candidates; however, adverse effects such as burning and irritation may limit their tolerance. Patients with vaginal cancer should be referred to a gynecologic oncologist for further management.

After a diagnosis of LSIL/VaIN 1 or p16 negative VaIN 2, we would recommend cotesting at 12 months. If the cotest is negative/negative, we recommend stopping further screening in women, who were inappropriately screened, and continue annual cytology or every 3-year cotesting in women posttreatment for HSIL or cancer. For women with persistent LSIL/VaIN 1 beyond 2 years without previous HSIL or cancer, it would be reasonable to extend the screening interval to every 2 to 3 years. After treatment for HSIL/VaIN 3 or p16+ VaIN 2, we recommend cotesting in 12 months and vaginal colposcopy if the result is hrHPV+ or LSIL or higher cytology.

Conclusions

Vaginal cancer is a rare HPV-associated malignancy that may be detected through vaginal cytology or HPV testing. It is not recommended to screen the general population for vaginal cancer. Women in high-risk groups who require close surveillance after treatment for cervical precancer or cancer should be followed per national guidelines. Women with abnormal vaginal screening tests posthysterectomy are at low risk of having HSIL/VaIN 2/3 and at even lower risk of having invasive vaginal cancer. We propose an algorithm to identify those women at highest risk that

TABLE 2. Proposed Subsequent Management of Histopathologic VaIN/Vaginal Cancer

Biopsy result	Management	Comments
LSIL/VaIN 1	Vaginal cotesting in 1 year repeat colposcopy if abnormal results ^a	For bulky warty disease can consider cosmetic treatment.
HSIL/VaIN 2/3 ^b	Treatment per current best practice	May vary by clinical site and could include laser ablation, excision/vaginectomy, topical treatment. Referral to gynecologic oncologist for large or complex lesions.
Invasive carcinoma	Treatment per current best practice	Referral to gynecologic oncologist.

LSIL indicates low-grade squamous intraepithelial lesion; VaIN, vaginal intraepithelial neoplasia; HSIL, high-grade squamous intraepithelial lesion.

^aFor persistent LSIL/VaIN 1 beyond 2 years without progression, can consider extending the screening and colposcopy interval to every 2 to 3 years, particularly in patients with immunosuppression who may never eradicate HPV but remain at risk.

^bSee text regarding treatment for VaIN 2.

should undergo colposcopy and biopsy of vaginal lesions. These include women with HSIL, ASC-H, or AGC vaginal cytology and women with persistent hrHPV infection for one year or longer or persistent ASC-US/LSIL for one year or longer. These recommendations are based on expert opinion, because evidence from prospective VaIN and vaginal cancer trials are lacking. Clinicians can use these recommendations to manage their average-risk patients with abnormal vaginal screening tests. Consultation with an expert should be considered for high-risk women or for situations outside the scope of this guidance.

Our exploration of the literature on VaIN and vaginal screening tests has defined areas of uncertainty. Further research on these topics is needed. In addition to conventional retrospective and cohort studies, this might be an opportunity to explore institutional or administrative databases for outcomes after an abnormal vaginal cytology or hrHPV test and after a diagnosis of VaIN. Although subject to the usual limitations of database studies, such an approach would harness larger numbers of VaIN and vaginal cancers from which to examine the contribution of vaginal tests and better define the natural history of VaIN and vaginal cancer.

ACKNOWLEDGMENTS

We would like to thank the American Society for Colposcopy and Cervical Pathology Board of Directors and the editor-in-chief of the *Journal of Lower Genital Tract Disease* for their assistance in editing the manuscript and providing feedback on earlier versions. We would also like to thank Ms Kamaria Nelson and Dr Brittany Lees for their assistance with the early PubMed searches. M.J.K. was supported in this work by grants NCI P50 CA098252 (PI Wu/Huh) and AHRQ K12 HS023009 (PI Saag); this work does not represent the views of either funding agency. The following authors have declared conflicts of interest: L.S.M. (personal fees for review of malpractice cases); T.M.D. (nonfinancial support from Hologic and honorarium paid to UCSF from Roche, TheVax Genetics, Ventana-Roche); P.E.C. (nonfinancial support from MTM, BD, Roche, Qiagen, and personal fees from Cepheid, BD, Roche, Inovio, Teva Pharmaceuticals, ClearPath, Merck, Gentical, and GE Healthcare); and W.K.H. (personal fees from Merck Vaccines and TheVax).

REFERENCES

- Aho M, Vesterinen E, Meyer B, et al. Natural history of vaginal intraepithelial neoplasia. *Cancer* 1991;68:195–7.
- Prevention CfDca. Human papillomavirus-associated cancers—United States, 2004–2008. *Morb Mortal Wkly Rep* 2012;61:258–61.
- Cramer DW, Cutler SJ. Incidence and histopathology of malignancies of the female genital organs in the United States. *Am J Obstet Gynecol* 1974;118:443–60.
- Daling JR, Madeleine MM, Schwartz SM, et al. A population-based study of squamous cell vaginal cancer: HPV and cofactors. *Gynecol Oncol* 2002;84:263–70.
- Smith JS, Backes DM, Hoots BE, et al. Human papillomavirus type-distribution in vulvar and vaginal cancers and their associated precursors. *Obstet Gynecol* 2009;113:917–24.
- Darragh TM, Colgan TJ, Cox JT, et al. The Lower Anogenital Squamous Terminology Standardization Project for HPV-Associated Lesions: background and consensus recommendations from the College of American Pathologists and the American Society for Colposcopy and Cervical Pathology. *J Lower Gen Tract Dis* 2012;16:205–42.
- Strander B, Andersson-Ellstrom A, Milsom I, et al. Long term risk of invasive cancer after treatment for cervical intraepithelial neoplasia grade 3: population based cohort study. *BMJ* 2007;335:1077.
- Hanselaar AG, Van Leusen ND, De Wilde PC, et al. Clear cell adenocarcinoma of the vagina and cervix. A report of the Central Netherlands Registry with emphasis on early detection and prognosis. *Cancer* 1991;67:1971–8.
- So KA, Hong JH, Hwang JH, et al. The utility of the human papillomavirus DNA load for the diagnosis and prediction of persistent vaginal intraepithelial neoplasia. *J Gynecol Oncol* 2009;20:232–7.
- Center for Disease Control and Prevention. HPV-associated cancer diagnosis by age. Available at: <http://www.cdc.gov/cancer/hpv/statistics/age.htm> Accessed July 25, 2015.
- Henson D, Tarone R. An epidemiologic study of cancer of the cervix, vagina, and vulva based on the Third National Cancer Survey in the United States. *Am J Obstet Gynecol* 1977;129:525–32.
- Minucci D, Cinel A, In sacco E, et al. Epidemiological aspects of vaginal intraepithelial neoplasia (VAIN). *Clin Exp Obstet Gynecol* 1995;22:36–42.
- Dodge JA, Eltabbakh GH, Mount SL, et al. Clinical features and risk of recurrence among patients with vaginal intraepithelial neoplasia. *Gynecol Oncol* 2001;83:363–9.
- Sillman FH, Fruchter RG, Chen YS, et al. Vaginal intraepithelial neoplasia: risk factors for persistence, recurrence, and invasion and its management. *Am J Obstet Gynecol* 1997;176(1 Pt 1):93–9.
- McCredie MR, Sharples KJ, Paul C, et al. Natural history of cervical neoplasia and risk of invasive cancer in women with cervical intraepithelial neoplasia 3: a retrospective cohort study. *Lancet Oncol* 2008;9:425–34.
- Gunderson CC, Nugent EK, Elfrink SH, et al. A contemporary analysis of epidemiology and management of vaginal intraepithelial neoplasia. *Am J Obstet Gynecol* 2013;208:410.e1–6.

17. Larsson GL, Helenius G, Andersson S, et al. Prognostic impact of human papilloma virus (HPV) genotyping and HPV-16 subtyping in vaginal carcinoma. *Gynecol Oncol* 2013;129:406–11.
18. Logani S, Lu D, Quint WG, et al. Low-grade vulvar and vaginal intraepithelial neoplasia: correlation of histologic features with human papillomavirus DNA detection and MIB-1 immunostaining. *Mod Pathol* 2003;16:735–41.
19. Saslow D, Solomon D, Lawson HW, et al. American Cancer Society, American Society for Colposcopy and Cervical Pathology, and American Society for Clinical Pathology screening guidelines for the prevention and early detection of cervical cancer. *CA Cancer J Clin* 2012;62:147–72.
20. Moyer VA. US Preventive Services Task Force. Screening for cervical cancer: U.S. Preventive Services Task Force Recommendation Statement. *Ann Int Med* 2012;156:880–891.
21. Herman JM, Homesley HD, Dignan MB. Is hysterectomy a risk factor for vaginal cancer? *JAMA* 1986;256:601–3.
22. Rimel BJ, Burke WM, Higgins RV, et al. Improving quality and decreasing cost in gynecologic oncology care. Society of gynecologic oncology recommendations for clinical practice. *Gynecol Oncol* 2015;137:280–4.
23. Sirovich BE, Welch HG. The frequency of Pap smear screening in the United States. *J Gen Intern Med* 2004;19:243–50.
24. De Vuyst H, Clifford GM, Nascimento MC, et al. Prevalence and type distribution of human papillomavirus in carcinoma and intraepithelial neoplasia of the vulva, vagina and anus: a meta-analysis. *Int J Cancer* 2009;124:1626–36.
25. Saraiya M, Unger ER, Thompson TD, et al. US assessment of HPV types in cancers: implications for current and 9-valent HPV vaccines. *J Natl Cancer Inst* 2015;107:djv086.
26. Alemany L, Saunier M, Alvarado-Cabrero I, et al. Human papillomavirus DNA prevalence and type distribution in anal carcinomas worldwide. *Int J Cancer* 2014;136:98–107.
27. Sinno AK, Saraiya M, Thompson TD, et al. Human papillomavirus genotype prevalence in invasive vaginal cancer from a registry-based population. *Obstet Gynecol* 2014;123:817–21.
28. Insinga RP, Liaw KL, Johnson LG, et al. A systematic review of the prevalence and attribution of human papillomavirus types among cervical, vaginal, and vulvar precancers and cancers in the United States. *Cancer Epidemiol Biomarker Prev* 2008;17:1611–22.
29. Pearce KF, Haefner HK, Sarwar SF, et al. Cytopathological findings on vaginal Papanicolaou smears after hysterectomy for benign gynecologic disease. *N Engl J Med* 1996;335:1559–62.
30. Frega A, French D, Piazzè J, et al. Prediction of persistent vaginal intraepithelial neoplasia in previously hysterectomized women by high-risk HPV DNA detection. *Cancer Lett* 2007;249:235–41.
31. Bansal M, Austin RM, Zhao C. Correlation of histopathologic follow-up findings with vaginal human papillomavirus and low-grade squamous intraepithelial lesion Papanicolaou test results. *Arch Pathol Lab Med* 2011;135:1545–9.
32. Castle PE, Schiffman M, Bratti MC, et al. A population-based study of vaginal human papillomavirus infection in hysterectomized women. *J Infect Dis* 2004;190:458–67.
33. Castle PE, Schiffman M, Glass AG, et al. Human papillomavirus prevalence in women who have and have not undergone hysterectomies. *J Infect Dis* 2006;194:1702–5.
34. Sugase M, Matsukura T. Distinct manifestations of human papillomaviruses in the vagina. *Int J Cancer* 1997;72:412–5.
35. Srodon M, Stoler MH, Baber GB, et al. The distribution of low and high-risk HPV types in vulvar and vaginal intraepithelial neoplasia (VIN and VaIN). *Am J Surg Pathol* 2006;30:1513–8.
36. Ferreira M, Crespo M, Martins L, et al. HPV DNA detection and genotyping in 21 cases of primary invasive squamous cell carcinoma of the vagina. *Mod Pathol* 2008;21:968–72.
37. Madsen BS, Jensen HL, van den Brule AJ, et al. Risk factors for invasive squamous cell carcinoma of the vulva and vagina—population-based case–control study in Denmark. *Int J Cancer* 2008;122:2827–34.
38. Chao A, Chen TC, Hsueh C, et al. Human papillomavirus in vaginal intraepithelial neoplasia. *Int J Cancer* 2012;131:E259–68.
39. Massad LS, Einstein MH, Huh WK, et al. 2012 updated consensus guidelines for the management of abnormal cervical cancer screening tests and cancer precursors. *Obstet Gynecol* 2013;121:829–46.
40. Koh WJ, Greer BE, Abu-Rustum NR, et al. Cervical cancer. *J Natl Compr Canc Netw* 2013;11:320–43.
41. Salani R, Backes FJ, Fung MF, et al. Posttreatment surveillance and diagnosis of recurrence in women with gynecologic malignancies: Society of Gynecologic Oncologists recommendations. *Am J Obstet Gynecol* 2011;204:466–78.
42. American Society for Colposcopy and Cervical Pathology. Colposcopy of the vagina. In: Cox JT, Mayeaux EJ Jr, eds. *Modern Colposcopy*. 3rd ed. Philadelphia: Lippincott Williams and Wilkins; 2012:400–2.
43. Gurumurthy M, Cruickshank ME. Management of vaginal intraepithelial neoplasia. *J Lower Gen Tract Dis* 2012;16:306–12.
44. Rhodes HE, Chenevert L, Munsell M. Vaginal intraepithelial neoplasia (VaIN 2/3): comparing clinical outcomes of treatment with intravaginal estrogen. *J Lower Gen Tract Dis* 2014;18:115–21.